

Research Article

AN ANATOMICAL COMPOSITION OF *KRIKATIKA MARMA* IN THE LIGHT OF MODERN ANATOMY – A CADAVERIC STUDY^{1,*} Pratibha Ramola, ²Nishant, ³Vijay Kumar Srivastava ⁴Vijay Laxmi Gautam and ⁴Dr. Ragini Pal^{1,2,4}Department of Rachana Sharir, Faculty of Ayurveda, Institute of Medical Sciences, Banaras Hindu University, Varanasi, India³Department of Panchakarma, Faculty of Ayurveda, Institute of Medical Sciences, Banaras Hindu University, Varanasi, IndiaReceived 17th December 2024; Accepted 15th January 2025; Published online 28th February 2025

Abstract

Background of the study: 107 essential *Marma* points are listed in ancient *Ayurvedic* scriptures. Among them is *Krikatika Marma*, which is situated at the junction of head and neck and is a type of *Vaikalyakar Marma*, and any injury to this *Marma* leads to *Chalmurdhata*. Using a cadaveric investigation, researchers attempted to determine the precise location of *Krikatika Marma* and its interaction with other anatomical entities (within the *Marma*'s perimeter). **Objectives:** To elucidate the anatomy of *Krikatika Marma* as per description available in *Ayurveda* and ancient literature and to analyze the anatomical structures that can be co-related in the light of modern anatomy. **Materials and methods:** A literary review of *Krikatika Marma* was done using all the concerned *Ayurvedic* and modern textbooks. Observation of the structures exposed during cadaveric dissection and correlation with textual description was done and a conclusion was drawn. **Results:** *Krikatika Marma* can be correlated to the atlanto occipital joint and atlantoaxial joint and the anatomical structures related to this joint

Keywords: *Krikatikamarma*, *Vaikalyakarmarma*, atlantooccipital, Atlanto axial joint.

INTRODUCTION

One of the most unique ideas expressed in the *Ayurvedic* scriptures is the idea of *Marma*. The location of *Marma*, where *Prana* lives, is a crucial point in the body where *Mamsa*, *Sira*, *Snayu*, *Asthi*, and *Sandhi* meet together. When subjected to trauma, they produce symptoms ranging from agonizing pain to fatality. *Marma* are the points where *Mamsa* (muscular tissue), *Sira* (blood vessels and nerves), *Snayu* (ligament, tendon, and nervous tissue), *Asthi* (osseous tissue), and *Sandhi* (joints) meet together. According to their nature, the *Pranas* are specifically located in these *Marmas*¹. *Marma* is one of the amazing treasures in the vast store of *Ayurvedic* knowledge. It stands for the scientific study of particular, crucial bodily locations (*Marmas*), which are known as the "seats of life" (*Prana*). (*Prana* is the essential life force that controls every living thing's subtle and physical functions. These areas are vital to the science of surgery since any damage to them has the potential to cause excruciating pain, impairment, loss of function, loss of feeling, or even death. They are referred to as "*Shalya Vishayardha*" (half of the science of surgery).² *Acharya Sushruta* states that *Marma sthan*, a vital point, should not be injured and should be kept intact even while doing surgeries³

MATERIALS AND METHODS

Literary study

Literary material will be collected from *Samhita Granthas* and modern books, national and international journals, magazines, seminars, conferences, internet material, previous works done, presented papers, databases, etc.

***Corresponding Author:** Pratibha Ramola,

Department of Rachana Sharir, Faculty of Ayurveda, Institute of Medical Sciences, Banaras Hindu University, Varanasi, India.

Cadaveric study

A thorough dissection of *Krikatika Marma* was carried out on human embalmed cadavers. with the help of dissection instruments at the dissection hall of Rachana Sharir Department, Institute Banaras Hindu University

Krikatika Marma

Krikatika Marma is situated at the junction of head and neck. This has been observed by all the *Acharya* along the *Acharya Sushruta*.

The meaning of the *Krikatika* word is "joint of neck"⁴ *Krikatika Marma* is situated at the junction of head and neck. This has been observed by all the *Acharya* along the *Acharya Sushruta*.

Acharya Vagbhatta follows *Sushruta* as he also suggested that *Krikatika Marma* is situated in the neck region, at the junction of head and neck. According to *Acharya Vagbhatta*, *Krikatika marma* is a *sandhi marma*. In prognostic status, it is *Vaikalyakar Marma*. Injury to this *Marma* causes *Chalmurdhata* i.e., unfixing of the head thus leading to death.⁵

Table 1. Details about *Krikatika Marma*

KRIKATIKA MARMA ^{6,7,8,9}	
Number	Two
Location	At the junction of head and neck
Measurement	Half <i>angula</i>
Structural	<i>Sandhi Marma</i>
Prognostic status	<i>Vaikalyakara Marma</i>
Injury result	<i>Chalmurdhata</i> i.e., instability of the head, the head keeps shaking and trembling involuntarily.

Krikatika marma is predominantly made of *sandhi* i.e., the joint between two bones, which forms the structure component of this *Marma*. Therefore it is classified under *sandhi marma*.

Anatomical structures related to *Krikatika Marma* according to different authors

According to Dr. Lele¹⁰ following structures are correlated with *Krikatika Marma*

- Atlanto occipital joint
- Occipital and Ist cervical bone(atlas)
- Rectus capitis lateralis
- Rectus capitis anterior
- Anterior and posterior primary ramus nerves
- Vertebral artery and veins

According to Dr. Ram Raksha Pathak¹¹ following structures are correlated with *Krikatika Marma*

- Atlanto- occipital membrane
- Lateral Atlanto -occipital ligaments

According to Dr. Raghuram¹² following structures are falling in the area of *Krikatika Marma*

- Atlanto-occipital joint
- Ligaments and membranes of Atlanto occipital joints

According to Dr. A.k. Pathak¹³ *Krikatika Marma* can be taken as the area over the atlantooccipital and atlantoaxial joint.

*Acharya Ghanekar*¹⁴ considered *Krikatika Marma* as the area present in the back of the neck

Cadaveric study

Steps of dissection¹⁵

Skin incision

The cadaver was placed in the prone position

The following incision was made one by one

- Use a scalpel to make a vertical midline incision through the skin from the external occipital protuberance to the seventh cervical spine. and a horizontal incision laterally from the lower end of the first incision. Reflect the skin flap, Remove the superficial and deep fascia from the surface of the trapezius
- Then Reflect the trapezius laterally by separating it from the superior nuchal line and dividing it vertically 1 cm from the vertebral spines. Then Identify the part of the obliquus capitis superior that is exposed. Detach the sternocleidomastoid from the superior nuchal line, expose the insertion of the splenius capitis, and Remove the fascia from the semispinalis capitis and the longissimus. Determine the attachments of these muscles.
- Then Reflect the longissimus capitis from the skull, and follow the occipital artery deep to the mastoid process over the obliquus capitis superior. And Trace the obliquus capitis superior to the transverse process of the atlas and to the skull.
- Detach the semispinalis capitis from the occipital bone, and turn it laterally, preserving the nerves that pierce it.

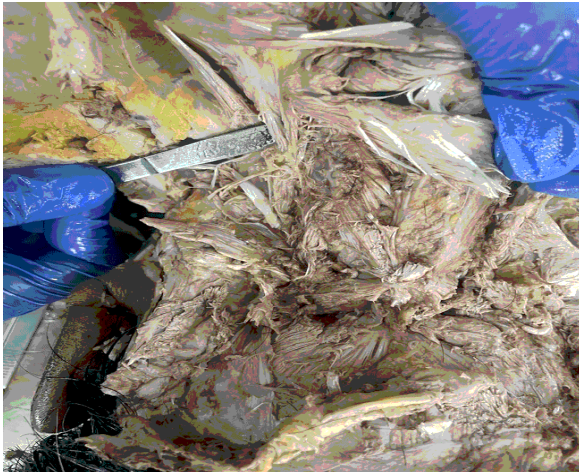
- Identify the suboccipital muscles and semispinalis cervicis, with the dorsal rami running over them. Define the attachments of the semispinalis cervicis
- Identify the dorsal ramus of the first cervical nerve, as it emerges between the vertebral artery and the posterior arch of the atlas. (The suboccipital triangle is difficult to dissect because of the dense fibrous tissue in it. If the branch of the dorsal ramus of the first cervical nerve to the
- semispinalis capitis has been retained, it can be followed to the ramus and the other branches traced from there. Alternatively, a communicating branch to the greater occipital nerve or the branch to one of the muscles of the triangle may be found and followed.) Remove the fascia from the triangle and the surrounding muscles. Re-define the attachments of the scalene muscles on both sides.
- Remove the scalenus anterior to expose the anterior and posterior intertransverse muscles which unite the corresponding tubercles of adjacent cervical transverse processes. They are separated from each other by the ventral rami of the cervical nerves. The dorsal rami passes posteriorly, medial to the posterior intertransverse muscles.
- The vertebral artery may now be exposed in the intertransverse spaces by removing the anterior intertransverse muscles.
- The right atlanto-occipital joint has been opened, and the right alar ligament and the longitudinal fibers of the cruciate ligament have been cut.
- Expose the ligaments uniting the cervical vertebrae by removing the remnants of muscle from the cervical articular processes and from the laminae and spines which have been removed in one piece.
- Remove any remaining parts of the posterior arch of the atlas and the laminae of the axis, to expose the parts of the membrane tectoria not damaged during the removal of the right half of the head.
- Cut through the membrane tectoria, and reflect it to expose the undamaged parts of the cruciate ligament and the accessory atlantoaxial ligaments. If the division of the skull was to the right of the midline, the apical ligament of the dens should still be present with the left half. It may be exposed by removing the superior band of the cruciate ligament.
- Identify the divided right alar ligament, and expose the left alar ligament passing from the side of the apex of the dens to the occipital condyle



Fig. 1. Incision on the cadaver

Table 2. Structures seen at the site of *Krikatika Marma* during the dissection process

Regional Anatomy of <i>Krikatika Marma</i>	
<i>Mamsa</i>	Lateral capitis lateralis, lateral capitis anterior
<i>Sira</i>	Vertebral arteries and veins
<i>Snayu</i>	Alar ligament, Atlanto-occipital ligament, transverse ligament, ligamentum nuchae
<i>Asthi</i>	Occipital bone, the atlas bone
<i>Sandhi</i>	Atlanto-occipital joint, Atlanto-axial joint

**Fig. 2. The structures related to *krikatika marma***

DISCUSSION OVER CADAVERIC STUDY

In the discussion section, it would be appropriate to elaborate on findings from the cadaveric study, correlations with traditional *Ayurvedic* texts, and clinical implications. The dissection of the back of the neck was carried out on a human cadaver following the guidelines of Cunningham's practical anatomy, Grant's dissector, and other applicable manuals. The cadaveric study was carried out on the cadaver in the Department of *Rachna Sharir* at the Institute of Medical Sciences Banaras Hindu University Varanasi. Every *Marma* of our body is a point where vital energy resides. The cadaveric study outlined the dissection process used to examine the *Marma*. This detailed approach allows for a deeper understanding of the structural anatomy and functional importance of the *Krikatika Marma*. The *Krikatika Marma* is described as a *Sandhi Marma*, according to *Parinama* it is a *Vaikalyakar Marma*. *Pramana* of *Krikatika Marma* is *Ardhangula* and it is two in number. Any injury to this *Marma* can lead to severe consequences termed *Chalmurdhata*, characterized by instability of the head and potentially death. *Marma* is the junction (meeting) place of *Mamsa* (muscular tissue), *Sira* (blood vessels and nerves), *Snayu* (ligament, tendon, and nervous tissue), *Asthi* (osseous tissue), and *Sandhi* (joints). The structure to be included under this *Marma* is the atlantooccipital joint, the atlantoaxial joint, the tectorial membrane, the alar ligament, the cruciate ligament, the apical ligament, the capsular ligament, the accessory atlantoaxial ligament, the anterior and posterior atlantooccipital membranes, Posterior ramus of C1, vertebral artery. These all structures are arranged bilaterally in a very small area i.e. *Half Angula* circumference. All ligaments are more or less responsible for the stability of the craniocervical junction. Overall, the provided sections offer a comprehensive overview of the *Krikatika Marma*, combining traditional knowledge with contemporary anatomical study, thereby enriching the understanding and potential applications of *Marma* science in healthcare practices.

Conclusion

Based on the literature study, cadaveric dissection, and discussion, it has been concluded that the location of *Krikatika Marma* lies between the junction of head and neck; it is a *Sandhi Marma* so as per the study we considered *Krikatika Marma* atlanto occipital joint and atlanto axial joint and its surrounding attached to the same within 1cm (*Half Angula*) area on either side and underlying in the depth of 1 cm.

REFERENCES

1. Sharir Sthana, Susruta Samhita Purvardha, Ayurveda Tatvasandipika, Hindi Vyakhya by Ambika Dutt, Chaukambha Publication Varanasi, 2008, page no. 69
2. Sharir Sthana, Susruta Samhita Purvardha, Ayurveda Tatvasandipika, Hindi Vyakhya by Ambika Dutt, Chaukambha Publication Varanasi, 2008, page no.77
3. Sharir Sthana, Susruta Samhita Purvardha, Ayurveda Tatvasandipika, Hindi Vyakhya by Ambika Dutt, Chaukambha Publication Varanasi, 2008, page no.71
4. Lele Avinash, Ranade Subash, and Frawley David: Secrets of Marma: The lost secrets of Ayurveda, a comprehensive textbook of Ayurvedic vital points. Delhi India: Chaukambha Sanskrit Pratishthan Varanasi, 1999; page no. 82.
5. Ashtanga Hridaya of Vagbhata Vidyotini, Hindi commentary by Kaviraja Atridev Gupta, Vaidya Yadunandana Updhyaya, Chaukambha Sanskrit Sansthan Varanasi, 2019, page no.267
6. Sharir Sthana, Susruta Samhita Purvardha, Ayurveda Tatvasandipika, Hindi Vyakhya by Ambika Dutt, Chaukambha Publication Varanasi, 2008, page no.75.
7. Sharir Sthana, Susruta Samhita Purvardha, Ayurveda Tatvasandipika, Hindi Vyakhya by Ambika Dutt, Chaukambha Publication Varanasi, 2008, page no.75.
8. Sharir Sthana, Susruta Samhita Purvardha, Ayurveda Tatvasandipika, Hindi Vyakhya by Ambika Dutt, Chaukambha Publication Varanasi, 2008, page no.75.
9. Sharir Sthana, Susruta Samhita Purvardha, Ayurveda Tatvasandipika, Hindi Vyakhya by Ambika Dutt, Chaukambha Publication Varanasi, 2008, page no.76.
10. Lele Avinash, Ranade Subash, and Frawley David: Secrets of Marma: The lost secrets of Ayurveda, a comprehensive textbook of Ayurvedic vital points. Delhi India: Chaukambha Sanskrit Pratishthan Varanasi, 1999, page no.82.
11. Pathak Ramraksha, Marma Vigyana, Chaukambha Sanskrit Series Office, Varanasi, 1949. Sharir Sthana, Susruta Samhita Purvardha, Ayurveda Tatvasandipika, Hindi Vyakhya by Ambika Dutt, Chaukambha Publication Varanasi, 2008, Page no.88.
12. Raghuram Y.S., Mansa. Krikatika Marma: Components, Location, Effect of Injury, <https://www.easyayurveda.com>
13. Dr. Ashutosh Pathak, Edited by Prof. H.H. Awasthi; (Anatomy of Marma) Chaukambha Orientalia, Varanasi, 1st edition: 2014, page no.154.
14. Sharirsthana Sushruta Samhita Ayurveda Rahasya Dipika hindi vyakhya by Bhaskar Govind Ghanekar Meherchand Lachhmandas Publication New Delhi, 2015
15. Dr. Rachel Koshi Cunningham's Manual Of Practical Anatomy The Joints Of The Lower Limb chapter 19 page no 267 United states, Oxford University Press, 16 edition.