International Journal of Science Academic Research
Vol. 07, Issue 11, pp.1744-1746, November 2026
Available online at http://www.scienceijsar.com
ISSN: 2582-6425

Case Report

GALLBLADDER CANCER DISCOVERED INCIDENTALLY ON A SPECIMEN FROM A CHOLECYSTECTOMY, ASSOCIATED WITH AN ISOLATED SPINAL METASTASIS: A CASE REPORT

***Zakaria KOULIBALY, El Hassouni SOUHAIB, Omar MKIRA, Othman ARSALAN, El Kheloufi SOUFIANE, Boudida HOUDA, Anass Zaghri, Madani MEHDI and Hadj Omar El MALKI**

Surgical Clinic 'A', Ibn Sina University Hospital, Rabat, Morocco
Faculty of Medicine and Pharmacy, Rabat, Mohammed V University, Souissi, Rabat, Morocco
Centre for Research in Clinical Epidemiology and Therapeutic Trials (CRECET) Rabat, Morocco

Received 16th September 2026; **Accepted** 18th October 2026; **Published online** 24th November 2026

Abstract

Gallbladder cancer is frequently discovered incidentally following cholecystectomy, whilst spinal metastases remain rare. We report the case of a 47-year-old female patient who underwent laparoscopic cholecystectomy for acute calculous cholecystitis. Pathological examination revealed a poorly cohesive cell carcinoma of the gallbladder classified as pT3Nx, associated with serosal invasion, vascular emboli, perineural infiltration and a positive cystic margin. Prior to staging investigations, the patient developed cervical and thoracic pain with neurological deficit in the right upper limb. Computed tomography (CT) and magnetic resonance imaging (MRI) demonstrated vertebral infiltration from C3 to D3 with epidural extension causing spinal cord compression, in the absence of visceral metastases. Due to the rapid deterioration in her general condition and the extent of the metastases, palliative care combining corticosteroid therapy and opioid analgesia was initiated. Radiotherapy could not be administered. The patient died two months after diagnosis. This case highlights that gallbladder cancer discovered incidentally may, from the outset, represent an aggressive systemic disease. Any spinal pain or neurological deficit in such patients should prompt a rapid investigation for vertebral-spinal cord involvement in order to adapt management accordingly.

Keywords: Gallbladder cancer, Spinal metastasis, Cholecystectomy, Spinal cord compression, Case study

INTRODUCTION

Gallbladder cancer is a rare tumour and remains the most common cancer of the biliary tract, with an incidence of approximately 3 per 100,000 people [1,2]. The most common histological type is adenocarcinoma. Diagnosis is often delayed due to its non-specific symptoms. Nearly 70 per cent of gallbladder carcinomas are discovered incidentally following cholecystectomy. The condition is suspected preoperatively in only around 30 per cent of cases [3]. This delay in diagnosis results in a poor prognosis. For advanced stages, the five-year overall survival rate is less than 5 per cent, and the median survival is less than six months. Conversely, early diagnosis combined with appropriate management can significantly improve the prognosis, with five-year survival rates reaching up to 75 per cent [1,4]. The disease usually progresses through local, lymph node, hepatic or peritoneal spread. Bone metastases remain rare, with an incidence of approximately 7.4 per cent, and spinal metastases are exceptional [3,5]. Owing to the rarity of spinal metastases in gallbladder cancer, data regarding their clinical, diagnostic and therapeutic characteristics remain limited. The aim of this study is to report a case of gallbladder cancer detected on the specimen following cholecystectomy, associated with concomitant spinal metastasis but without visceral metastasis, and to discuss its clinical, radiological and therapeutic characteristics in the light of the literature.

Corresponding Author:** ***Zakaria KOULIBALY,
Surgical Clinic 'A', Ibn Sina University Hospital, Rabat, Morocco.

CASE REPORT

We report the case of a 47-year-old female patient with a history of a right isthmolobectomy for a thyroid nodule, performed 20 years ago, with a histopathological examination showing no signs of malignancy. She was admitted for pain in the right upper quadrant that had been developing for 5 days, resembling hepatic colic, associated with vomiting, but without fever or bowel dysfunction. There were no clinical signs of cholestasis, and her general condition was stable (WHO 0).The clinical examination revealed a stable patient, afebrile at 37.8 °C, with no jaundice. The abdominal examination revealed tenderness in the right upper quadrant, with a positive Murphy's sign, but no palpable mass. Furthermore, there were no focal neurological signs or radicular pain. In view of the abdominal pain, an abdominal ultrasound scan was performed, which revealed a distended gallbladder with a wall thickness of 7.4 mm, two large gallstones measuring 11 mm and 17 mm with perigallbladder infiltration, and no dilatation of the bile ducts. The complete blood count showed a white blood cell count of 6,300/mm³ and a C-reactive protein level of 15 mg/L, with no signs of cholestasis or cytolysis. A diagnosis of acute calculous cholecystitis was made. A four-trocar laparoscopic cholecystectomy was performed. On examination, the gallbladder was distended, with no visible liver or peritoneal lesions. A retrograde cholecystectomy was performed, involving difficult dissection of the gallbladder from its bed following control of the cystic pedicle. The specimen was extracted in a bag via the umbilical port without rupture. The

immediate post-operative course was uneventful. Pathological examination revealed a 3 cm poorly cohesive cell carcinoma of the gallbladder. The tumour infiltrated the serosa with vascular emboli and perineural sheathing. Multifocal lesions of high-grade intraepithelial biliary neoplasia were also present. The resection margin of the cystic duct was invaded. The lesion was classified as pT3Nx. A thoraco-abdomino-pelvic CT scan was requested as part of a staging assessment with a view to possible further surgery. Prior to the scan, the patient presented with progressive spinal pain, predominantly in the cervicodorsal region. This pain was accompanied by neck stiffness and paraesthesia. The clinical examination also revealed muscle weakness in the right upper limb, rated at 3/5, with no abnormality in osteotendinous reflexes. The clinical examination revealed pain in the thoracic spine, with no involvement of the lower limbs or other signs of underlying pathology. The patient's general condition then deteriorated rapidly, with a WHO score of 4 and the onset of cholestasis, with GGT at 1,060 IU/L and PAL at 724 IU/L, without cytolysis.

The thoraco-abdominal-pelvic CT scan revealed no focal liver lesions, nor any pulmonary or peritoneal metastases. However, it did reveal intra- and retroperitoneal lymphadenopathy, as well as osteolytic lesions of the thoracic spine from D1 to D3, associated with moderate anterior wedge-shaped compression of D2, infiltration of the prevertebral soft tissues and anterior epidural extension, suggestive of spinal metastases (Figure 1). The spinal MRI confirmed tumour infiltration of the cervicodorsal spine from C3 to D3, moderate compression of C5 and D2, and epidural and soft-tissue involvement causing spinal cord compression. The case was discussed at a multidisciplinary team meeting. Given the extent of spinal metastases, the spinal cord compression and the rapid deterioration in her general condition (WHO 4), a palliative management approach was adopted, combining corticosteroid therapy and opioid analgesia. Decompressive radiotherapy was considered but could not be carried out due to the rapid deterioration in her clinical condition. The patient died two months after diagnosis.

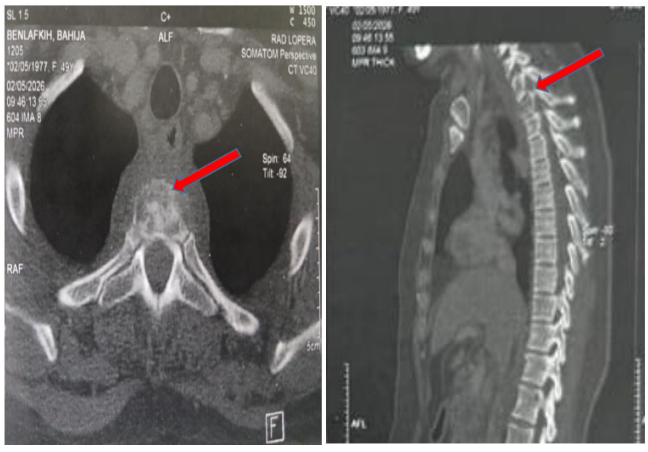

Figure 1. Thoraco-abdominal-pelvic CT scan showing osteolytic lesions of the thoracic spine from D1 to D3, with anterior wedge-shaped compression of D2, infiltration of the prevertebral soft tissues and anterior epidural extension

DISCUSSION

The significance of this case lies in the progression of a gallbladder cancer, discovered incidentally, to an initial spinal metastasis with spinal cord compression. The occurrence of this lesion without any identifiable visceral metastases on the staging work-up constitutes an unusual presentation. This presentation demonstrates that a newly diagnosed gallbladder cancer with a high histological prognostic risk should not be considered from the outset as a strictly localised disease and may represent a systemic disease at the time of diagnosis [6]. Incidental gallbladder cancers are frequently diagnosed following a cholecystectomy performed for benign gallstone disease, due to non-specific clinical and radiological signs. Routine histopathological examination of surgical specimens remains essential for their identification [6,7]. In our case, the diagnosis was made retrospectively following a cholecystectomy performed for calculous cholecystitis. The incidental nature of the diagnosis does not preclude the possibility of tumour aggressiveness.

Adverse histoprognostic factors, notably pT3 stage with serosal invasion, vascular emboli, perineural invasion and a positive cystic margin, are associated with an increased risk of recurrence and metastatic spread [8,9]. These factors may explain the rapid metastatic progression observed in our case, despite the absence of identifiable visceral metastases at the initial assessment. Bone metastases from gallbladder cancer are rare (7 per cent) and predominantly affect the axial skeleton [3,10]. Vertebral involvement is exceptional and usually occurs in the context of known metastatic disease [11]. In our case, spinal involvement was the primary site of dissemination, with no identifiable liver, lung or peritoneal metastases. This presentation suggests early haematogenous spread as a possible initial course of an aggressive gallbladder cancer.

Gallbladder cancer spreads mainly by direct extension to the liver, via the lymphatic system to regional lymph nodes, and by peritoneal dissemination. Isolated vertebral involvement could be explained by haematogenous spread via Batson's vertebral venous plexus, allowing direct access to the spine without necessarily passing through the pulmonary or hepatic filters (11). In our case, the presence of tumour-derived vascular emboli and the absence of identified visceral metastases support this mechanism, although they do not allow the exact route of spread to be confirmed.

Vertebral metastases present with variable radiological features, which may be lytic, sclerosing or mixed depending on the primary tumour [11]. In our case, the CT scan showed osteolytic lesions at D1 to D3 with epidural extension, a finding also reported in the rare published cases of vesicular cancer with spinal involvement [4,12]. The epidural extension, which causes spinal cord compression, explains the neurological symptoms observed. MRI remains the gold standard for assessing spinal cord involvement, epidural extension and neurological complications [11]. In a patient with gallbladder cancer, the onset of persistent spinal pain or neurological deficit should raise suspicion of a vertebro-spinal localisation and lead to the prompt performance of a spinal MRI scan.

In the presence of distant metastases, the management of gallbladder cancer is generally palliative, combining systemic treatment and, where necessary, local treatments such as radiotherapy [8]. In our case, the patient's deteriorating general condition and spinal cord compression limited treatment to corticosteroid therapy and analgesics. Radiotherapy, which is indicated in cases of spinal cord compression, could not be

carried out. In the absence of metastases, curative surgery involving additional liver resection and lymph node dissection would have been considered from stage pT1b onwards, following a comprehensive staging assessment [8]. Bone metastases from gallbladder cancer are associated with a poor prognosis. In the analysis by Gera et al., their presence was correlated with a significant reduction in overall survival [3]. Our observation is consistent with these findings, with a rapidly deteriorating clinical course leading to death two months after diagnosis. This course suggests that an initial vertebral involvement may be a marker of a biologically aggressive disease.

This report highlights the inherent limitations of a single clinical case, which restrict the generalisability of the findings. The diagnosis of spinal metastasis is based on clinical and radiological evidence, without histological confirmation. Finally, the mechanism of spread via Batson's venous plexus remains hypothetical.

Conclusion

This observation illustrates that gallbladder cancer discovered incidentally may represent an aggressive systemic disease at the time of diagnosis, even in the absence of identifiable visceral metastases on the initial work-up. Adverse histoprognostic factors should prompt a rigorous assessment of the risk of dissemination. The onset of spinal pain or neurological signs should prompt a rapid investigation for vertebral or spinal cord involvement using MRI, in order to adapt management at an early stage.

Informed consent: Informed consent was obtained from the patient during her lifetime for the publication of this clinical case and associated data.

Conflict of interest: The authors declare that they have no conflict of interest.

REFERENCES

1. Afzal A, Liu YY, Noureen A, Rehman A, Iftikhar M, Afzal H, et al. Epidemiology of gall bladder cancer and its prevalence worldwide: a meta-analysis. *Orphanet J Rare Dis*. 27 mars 2025;20(1):143. Doi:10.1186/s13023-025-03652-0
2. Ka I, Faye M, Diop PS, Faye ABNAC, Ndoye JM, Fall B. Biliary tract cancerss: epidemiological, clinical and therapeutic aspects of 20 cases Pan Afr Med J. 4 janv 2018;29:13. doi:10.11604/pamj.2018.29.13.9922.
3. Gera K, Kahramangil D, Fenton GA, Martir D, Rodriguez DN, Ijaz Z, et al. Prognosis and Treatment Outcomes of Bone Metastasis in Gallbladder Adenocarcinoma: A SEER-Based Study. Cancers. janv 2023;15(20):5055. Doi:10.3390/cancers15205055
4. Joshi MK, Joshi R, Chadha M, Alam SE, Varshneya H, Kumar S. Gall Bladder Carcinoma Presenting with Spinal Metastasis: A Rare Phenomenon. Indian J Palliat Care. 2013;19(2):113-5. doi:10.4103/0973-1075.116711.
5. Goetze TO. Gallbladder carcinoma: Prognostic factors and therapeutic options. World J Gastroenterol. 21 nov 2015;21(43):12211-7. doi:10.3748/wjg.v21.i43.12211.
6. Hu X, Zeng D, Wen N, Wang Y, Lu J, Li B. Prognostic factors in gallbladder cancer: a comprehensive systematic review and meta-analysis. Hepatobiliary Surg Nutr. 1 juin 2025;14(3):374-97. Doi:10.21037/hbsn-23-502.
7. Pyo JS, Son BK, Lee HY, Oh IW, Chung KH. Incidental Carcinoma after Cholecystectomy for Benign Disease of the Gallbladder: A Meta-Analysis. J Clin Med. 14 mai 2020;9(5):1484. Doi:10.3390/jcm9051484.
8. Saikia K, Xu Z, Azordegan N, Ahsan BU. Incidental diagnosis of gallbladder carcinoma during or after routine cholecystectomy: A retrospective study with emphasis on clinicopathologic findings. World J Clin Oncol. 24 juill 2025;16(7):104663. doi:10.5306/wjco.v16.i7.104663.
9. Varshney S, Butturini G, Gupta R. Incidental carcinoma of the gallbladder. Eur J Surg Oncol. févr 2002;28(1):4-10. doi:10.1053/ejso.2001.1175.
10. Sameer G, Naseem A, Vijay K, Sanjeev M, Jaswant J, Vadakkanchery AS. Skeletal metastasis in gallbladder cancer from a high-volume tertiary care center of north India: a series of rare occurrence. J Gastrointest Cancer. mars 2015;46(1):36-41. Doi:10.1007/s12029-014-9666-z.
11. Zhu M, Liu X, Qu Y, Hu S, Zhang Y, Li W, et al. Bone metastasis pattern of cancer patients with bone metastasis but no visceral metastasis. Journal of Bone Oncology. 1 avr 2019;15:100219. doi:10.1016/j.jbo.2019.100219
12. Bouziane A, Tijani M, Latib R, Chami I, Najib Boujida M. The various MRI features of vertebral and spinal cord metastases: a report on 10 cases.Journal of Neuroradiology. 1 mars 2016;43rd Congress of the SFNR43(2):96-7. doi:10.1016/j.neurad.2016.01.068
13. Prakash M, Aiyappan SK, Kumar A, Sreenivasan R, Yadav TD, Khandelwal N. Solitary skeletal metastasis in carcinoma gallbladder: two case reports. Cancer Imaging. 8 mai 2010;10(1):121-3. doi:10.1102/1470-7330.2010.0014.

****